



Acute and 28-day subchronic toxicity studies of mangiferin, a glucosyl xanthone isolated from *Mangifera indica* L. stem bark

[Toxicidad aguda y subcrónica (28 días) de la mangiferina, una glucosil xantona aislada de la corteza de *Mangifera indica* L.]

Yalena Prado¹, Nelson Merino², Jhoany Acosta¹, José A. Herrera³, Yilian Luque⁴, Ivones Hernández⁵, Elisa Prado¹, Gabino Garrido⁶, René Delgado², Idania Rodeiro^{5*}

¹Departamento de Bioingeniería, Facultad de Ingeniería Eléctrica, Universidad Politécnica José Antonio Echeverría, Marianao, e/ 114 y Ciclovía;

²Laboratorio de Farmacología, Centro para la Investigación y Desarrollo de Medicamentos, 26 y 51, Plaza de la Revolución, 10400;

³División de Nanomateriales, Instituto de Ciencia y Tecnología de Materiales (IMRE), Universidad de La Habana, Zapata y G, Vedado;

⁴Departamento de Inmunología, Centro de Química Biomolecular, 200 y 21, Atabey, Playa;

⁵Departamento de Farmacología, Centro de Bioproductos Marinos (CEBIMAR), Loma 37, Vedado, 10400, La Habana, Cuba.

⁶Departamento de Ciencias Farmacéuticas, Facultad de Ciencias, Universidad Católica del Norte, Angamos 0610, Antofagasta, Chile.

E-mail: idania.rodeiro@infomed.sld.cu

Abstract

Context: Pharmacological properties of mangiferin have been reported, but few studies have investigated mangiferin toxicity.

Aims: To study the acute and 28-day toxicity effects of mangiferin in rodents.

Methods: Single doses of mangiferin were administered by oral or i.p. route or were applied dermally to Sprague-Dawley rats and Balb/C mice. Clinical symptoms of animals were observed during 14 days after treatment. Animals also received single oral doses daily for 28 consecutive days. Blood biochemistry, hematology and pathology findings were reported.

Results: In the acute study, no toxic effects were observed after dermal exposure to mangiferin 2000 mg/kg but transient dyspnea, flank position and piloerection were observed after oral administration to this xanthone. I.p. administration induced similar toxicity signs, but at the highest dose (2000 mg/kg) all mice, one female rat and one male rat died. Rats orally treated with mangiferin (250-1000 mg/kg) for 28 days did not show any abnormal clinical signs or hematology alterations, when compared to control group animals. Histopathological alterations like vacuolar degeneration, necrosis and increment of apoptosis of the acinar cells were observed in the exocrine pancreas of rats at 1000 mg/kg. This suggesting that exocrine pancreas was the target organ for mangiferin's toxicity.

Conclusions: These studies indicated that acute and subchronic toxicities of mangiferin for oral exposure are low.

Keywords: Acute dose; mangiferin; repetitive toxicity assay; toxicological studies; xanthone.

Resumen

Contexto: Las propiedades farmacológicas de la mangiferina han sido previamente reportadas pero su toxicidad ha sido poco estudiada.

Objetivos: Estudiar la toxicidad aguda y subcrónica tras 28-días de administración de mangiferina a roedores.

Métodos: Dosis únicas de mangiferina fueron administradas oralmente, por vía i.p. o se aplicaron dérmicamente a ratas Sprague Dawley y ratones Balb/C. Los síntomas clínicos de los animales fueron observados durante 14 días después del tratamiento. Otros animales recibieron diariamente dosis únicas por vía oral durante 28 días consecutivos. Los datos de la bioquímica sanguínea, hematología y los hallazgos patológicos fueron también reportados.

Resultados: No se observaron efectos tóxicos en el estudio agudo después de la exposición dérmica a 2000 mg/kg de mangiferina. Se observó disnea transitoria, cambios en la postura normal del animal y piloerección después de la administración oral. La administración por vía i.p. indujo signos tóxicos similares, pero a la dosis más alta (2000 mg/kg) todos los ratones murieron, una rata hembra y otra macho. Las ratas tratadas oralmente con mangiferina (250-1000 mg/kg) durante 28 días no mostraron señales clínicas anormales o alteraciones de los valores hematológicos, en comparación con el grupo control. Otras alteraciones de tipo histopatológico fueron observadas en el páncreas exocrino de ratas tratadas con dosis de 1000 mg/kg, estas fueron: degeneración vacuolar, necrosis y aumento de la apoptosis de las células acinares. Lo anterior sugirió que el páncreas exocrino es el órgano diana para la toxicidad de la mangiferina.

Conclusiones: Estos estudios indicaron que son bajas la toxicidad aguda y subcrónica de la mangiferina cuando es administrada por vía oral.

Palabras Clave: Dosis aguda; ensayo de dosis repetidas; estudios toxicológicos; mangiferina; xantona.

ARTICLE INFO

Received | Recibido: December 4, 2014.

Received in revised form | Recibido en forma corregida: February 4, 2015.

Accepted | Aceptado: February 19, 2015.

Available Online | Publicado en Línea: February 28, 2015.

Declaration of interests | Declaración de Intereses: The authors declare no conflict of interest.

Funding | Financiación: This work was supported by projects PNAP-CIDEM 613007 (Cuba), VLIR-OUS 2011-062 (Belgium) and FONDECYT 1130601 (Chile).

Academic Editor | Editor Académico: Marisela Valdés.



INTRODUCTION

Polyphenols are a large group of natural compounds that include flavonoids, anthocyanins and tannins, among others. They are widely distributed in food sources, and they are ingested daily in significant quantities as part of the diet. Potent antioxidant effects have been reported for these molecules, which depend on their free-radical scavenging capacity and iron-chelating activity, among other biological properties (Pauletti et al., 2003; Wu et al., 2008; Nuñez et al., 2009). They are also the broad source of antioxidants consumed by humans and are promising candidates to explain the protective effects of fruit and vegetables against oxidative damage related diseases like coronary heart diseases, stroke, and cancer. Other properties have also been attributed to natural polyphenols: antiviral, antibacterial, anti-inflammatory, neuroprotective and antitumor action, as well as the ability to modulate certain signalling pathways like nuclear factor-kappa B activation (Aggarwal and Shishodia, 2006; Chen and Dou, 2008; Campos et al., 2009; Darvesh et al., 2010; Noratto et al., 2010). In short, plant polyphenols are a versatile group of chemical entities with many potential human benefits like phytomedicines that raise the necessity for increasing available data about their risk-benefit margin.

Mangiferin is a glucosyl xanthone widely distributed in higher plants, i.e. Anacardiaceae and Gentianaceae families, and recently it has attracted the attention of many researchers in different parts of the world. Several properties have been reported for mangiferin, for instance: anti-oxidant, anti-diabetic, anti-cancer, immunomodulatory, anti-genotoxic and anti-inflammatory (Muruganandan et al., 2005; Garrido et al., 2004; 2007; Leiro et al., 2004; Dar et al., 2005; Amazzal et al., 2007; Rajendran et al., 2008; Lee et al., 2009; Prabhu et al., 2009; Satish et al., 2009; Li et al., 2010; Viswanadh et al., 2010). Some studies have been performed in Cuba with isolated and purified mangiferin from one standardized aqueous stem bark of *Mangifera indica* L. tree (mango) extract (MSBE). They support the potential therapeutic uses of mangiferin in diseases where oxidative stress and

inflammation are highly present (Sanchez et al., 2000; Garrido et al., 2004; Rodeiro et al., 2008; 2014; Garcia et al., 2011; Garrido-Suarez et al., 2014; Rodriguez et al., 2014; Tolosa et al., 2014).

However, few studies have been performed for describing the potential toxicological effects of this compound. Jagetia and Baliga (2005) reported that intraperitoneal (i.p.) LD₅₀ of mangiferin in DBAxC57BL mice was 400 mg/kg. Govindraj et al. (2009) showed that the mangiferin was not mutagenic to *Salmonella typhimurium* strains by using the Ames assay. Studies performed by us showed mangiferin is non-cytotoxic and non-genotoxic in a battery of assays (Rodeiro et al., 2012). Previous studies were performed to evaluate the toxicity effects of MSBE, where mangiferin is the principal component (Garrido et al., 2009). They show that the LD₅₀ of MSBE administered to rats and mice by oral route is higher than 5000 mg/kg, reporting only some transient toxicity signs like dyspnoea, flank position and piloerection as well as reduced locomotion activity in the animals exposed to the extract. Similar toxicity signs are observed when MSBE is administered to animals by i.p. route, but under these conditions the extract is considered toxic according to the Acute Toxic protocols. MSBE is not toxic to Sprague-Dawley rats after a 90-day exposure to oral doses up to 1 000 mg/kg.

Expectations around the possible beneficial use of mangiferin in humans as a new medicinal drug make necessary the toxicological characterization of this natural product. To accomplish this purpose, we carried out oral acute, dermal and i.p. toxicity assays in rats and mice and a 28 day-long repetitive doses study of mangiferin in rats.

MATERIAL AND METHODS

Materials

The batch of mangiferin (No. 010) used in the study was supplied by the Laboratory of Chemistry for Natural Products at the Drug Research and Development Center of Cuba (CIDEM, Havana, Cuba) and was assessed with a validated HPLC-based method (Nuñez et al., 2002). Mangiferin (1,3,6,7-tetrahydroxy xanthone-C2-β-

d-glucoside) was purified from the MSBE by extraction with methanol according to the standard method as described (Nuñez et al., 2002); purity was 92%.

Animals

Rats and mice were obtained from the Centro para la Producción de Animales de Laboratorio (CENPALAB, Havana, Cuba) and were acclimatized to the environmental conditions for one week before tests. Male and Female Sprague-Dawley rats weighing 150-200 g and Balb/C mice of both sexes weighing 20-25 g were used in an acute toxicity assay. Male and female rats used in a repetitive dose toxicity assay were six weeks old at the onset of dosing. Animals were housed in plastic and stainless-steel grid-floored cages, which were kept at $23 \pm 2^\circ\text{C}$, relative humidity 40-60%, 12 h light/dark cycles with food and water *ad libitum*. The mice and rats employed were randomly distributed for tests. In the acute toxicity studies, 3 animals/sex/doses were used, and for the repetitive dose assay 12 animals/sex/groups were randomly assigned to 4 groups (control, low, medium and high dose groups).

Experimental designs

All studies were in compliance with Good Laboratory Practice (GLP) standards. The experiments were conducted in accordance with the ethical guidelines for investigations in laboratory animals and were approved by the Ethical Committee for Animal Experimentation of the Drug Research and Development Center (CIDEM), La Habana, Cuba.

Acute oral toxicity study

A single dose level of mangiferin at 2 000 mg/kg per body weight was administered via gastric intubation to mice and rats according to the ATC method described in the OECD Protocol 423 (2000). Mangiferin was suspended in carboxymethyl cellulose (CMC) 0.5% and administered at 10 mL/kg to mice and 5 mL/kg to rats.

Acute dermal toxicity study

A volume of 0.1 mL of mangiferin was administered dermally to the dorsal region of each animal (as a single dose of 2 000 mg/kg per body weight in a shaved area), representing the 10% of the total body surface area, according to OECD Protocol 434 (2004).

Acute i.p. toxicity study

The doses for mice and rats were selected according to the Acute Toxicity Class (ATC) method (OECD, 2000). The first dose of mangiferin was 2000 mg/kg per body weight following a second one of 300 mg/kg per body weight dissolved in Tween 20 (0.4% in distilled water).

Observations of clinical signs

Animals were closely observed during the first 24 h post-administration for detecting clinical signs that included morbidity and mortality. The time of appearance, duration and intensity of every clinical sign were also recorded. Animals were also observed for the remaining 14 days in order to detect and record changes in appearance, overt behaviour, skin, fur, eyes, and mucous membranes, as well as any disturbances in respiration, autonomic or central nervous system. Body weight data were recorded at the beginning and the end of the study. The incidence of gross pathological changes was also observed during the necropsy performed at day 14 in each study.

Repetitive dose oral toxicity study

The test material was administered by single oral intubations during 28 consecutive days. Four experimental groups (12 animals/sex/groups) were included: three groups were treated with mangiferin at doses of 250, 500 and 1000 mg/kg and the control group received equivalent volumes of CMC (0.5%). During the administration period, animal general appearance was observed every day and body weight was measured weekly and at necropsy.

At the end of the study, animals were fasted for 16-19 h and on the necropsy day they were anesthetized with diethyl ether. Blood samples

were collected from the abdominal aorta and around 1 mL of blood was treated with EDTA for determining hematocrit (Ht), haemoglobin concentration (Hb), differential percentage of total leukocytes (lymphocytes, monocytes, eosinophils), erythrocytes and platelet count. Analyzes were performed by using a Haematology analyzer F-850 (Sysmex Co., LTD). The differential white blood count was measured by using the Brecher method and the May-Grunwald-Giemsa staining method. Serum from blood samples were collected and the following parameters: aspartate aminotransferase (AST), alanine aminotransferase (ALT), glucose, total cholesterol, triglyceride, uric acid, creatinine (CR) and albumin concentration were measured by means of a 7150 automatic analyzer (Hitachi Co., Ltd.).

Pathological examination

During necropsy, the abdominal, thoracic and cranial cavities of each animal were examined while the liver, spleen, heart, kidneys, lungs, thymus and brain were weighed (Sartorius Universal Scale, Goettingen, Germany). Tissue samples were taken from all animals in the study: Samples came from the above mentioned organs and from lymph nodes, bone red marrow, pituitary gland, thyroid with parathyroid, larynx/trachea, bronchi, salivary glands, tongue, oesophagus, stomach, small and large intestines, pancreas, penis, urinary bladder, vagina, skeletal muscle, skin, eyes, Harderian glands, Zymbal gland, sciatic nerve, cerebrum, cerebellum and spinal cord. Samples were preserved in 10% buffered formaldehyde, embedded in paraffin, sectioned with a rotary microtome (Leitz microtome, Wetzlar, Germany), stained with hematoxylin and eosin and examined by light microscopy. An Olympus BH2 microscope (Olympus Optical Co., Ltd. Tokyo, Japan) was used for these observations.

Statistical analysis

Means and standard deviations of body weight, food consumption, haematology, blood chemistry and relative organ weights were

determined. One-way breakdown ANOVA followed by the Dunnett multiple comparison tests were used in order to compare each group with controls. Relative organ weight data was transformed as $\arcsin(\sqrt{\text{datum}})$ to achieve normality. Homoscedasticity was assessed by the Bartlett test for homogeneity of variances. In the absence of variance homogeneity, the Kruskal-Wallis test was used. Statistical significance level was $p < 0.05$.

RESULTS

Oral acute studies of mangiferin in rodents

All animals survived the 14-day observation period after oral administration of 2000 mg/kg of mangiferin, and their body weight increased during this time. Only transitory piloerection and decrease in the motor activity were observed during the first three hours after administration. It was not found gross pathology alterations at necropsy, and no significant changes were observed in any organ (data not shown).

Dermal acute studies of mangiferin in rodents

No toxic effects were observed in mice and rats after dermal exposure to 2 000 mg/kg mangiferin doses. No were detected deaths neither clinical findings related to mangiferin nor remarkable body weight changes nor other local reaction associated with treatment.

Intraperitoneal acute studies of mangiferin in rodents

Some animals died in the i.p. acute toxicity assays within 72 h of treatment. All mice administered with the highest dose level (2000 mg/kg) died, but rats tolerated better than mice with mortality only in one male and one female animal. However, no mice or rats died at the 300 mg/kg dose level groups. Signs observed in animals (rats and mice) prior to death were: decreased motor activity, decreased response to the stimulus, prostration, piloerection, ataxia and dyspnea. The animal that survived showed just piloerection during the whole period of the

experiment. No significant changes were detected at necropsy in any organs from the animals that survived.

Repetitive doses oral toxicity study of mangiferin in rats

No animals died during the 28 day-long oral toxicity study of mangiferin in rats. In the 250 and 500 mg/kg groups, there were no abnormal findings in males or females. Only few toxicity signs were observed during the study in the animals treated with the highest dose of mangiferin (1000 mg/kg). Two female rats showed the following toxicity signs, after day 21: decreased motor activity, decreased response to the stimulus, prostration, piloerection and ataxia, all signs were kept until sacrifice on day 28. Three male rats showed piloerection, which coincidentally was the most persistent finding observed in the acute study. There were no significant differences ($p > 0.05$) in body weight between groups during the administration period (Fig. 1). Body weight gain and food consumption were unaffected by mangiferin exposure during the trial.

No significant differences were observed ($p > 0.05$) in the haematological and clinical chemistry parameters in female and male rats (Tables 1 and 2). These parameters were within normal range according to physiological background data, and the historical values reported for these animals (Alemán et al., 1998).

The results of the absolute weight of organs are shown in Table 3. Gross necropsy findings did not reveal changes in any organs and tissues examined. There were no statistically significant differences between the control group and the mangiferin-treated groups in organ weight. Recorded values were also within the normal physiological range described for this species. A search for histopathological changes was also carried out to the organs and tissues of controls and animals treated with the different dose levels of mangiferin. As it can be observed (Table 4), the exocrine pancreas was the unique target organ for mangiferin toxicity. The main findings observed were: vacuolar degeneration, basophilic cytoplasm changes, necrosis and apoptosis of the acinar cells, which was explained as diffuse non-inflammatory exocrine pancreas atrophy. No other inflammatory reaction was found (Fig. 2).

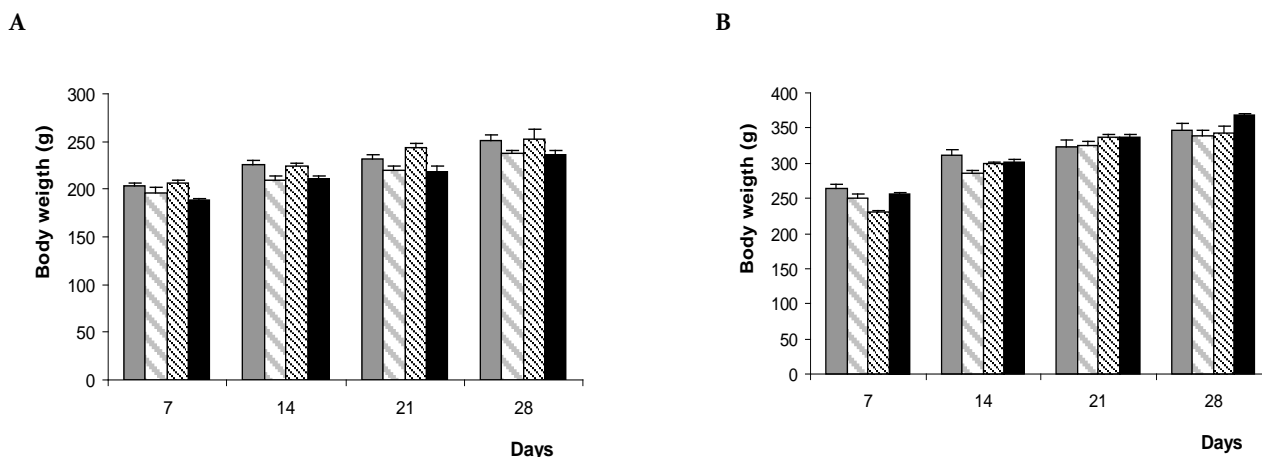


Figure 1. Body weight of female (A) and male (B) rats during the study of repetitive oral dose toxicity. Control groups are represented by solid gray bars while doses of mangiferin were 250 mg/kg (light gray stripes), 500 mg/kg (black dotted), and 1000 mg/kg (solid black). Data are presented as mean \pm SD. No significant differences were observed between groups, Dunnett's Test, $p > 0.05$.

Table 1. Blood biochemical parameters in rats after 28 days of mangiferin oral administration.

Dose (mg/kg)	Glucose (g/L)	Creatinine (mmol/L)	ALT (U/L)	AST (U/L)	Cholesterol (mmol/L)	Triglycerides (mmol/L)	Uric acid (mmol/L)	Albumin (g/L)
Female								
Control	5.2 ± 2.0	45.3 ± 13.0	42.7 ± 9.7	247.0 ± 51.0	0.47 ± 0.2	0.78 ± 0.1	95.1 ± 24.6	36.7 ± 3.4
250	4.4 ± 1.3	51.3 ± 15.9	47.9 ± 9.3	297.8 ± 54.2	0.84 ± 0.3	0.82 ± 0.2	150.4 ± 38.3	40.3 ± 2.6
500	4.5 ± 1.2	56.0 ± 14.0	51.3 ± 16.5	279.1 ± 66.1	0.49 ± 0.4	0.95 ± 0.3	146.6 ± 95.1	39.6 ± 3.8
1000	4.5 ± 0.9	49.9 ± 11.3	53.6 ± 16.0	284.1 ± 49.7	0.55 ± 0.3	0.78 ± 0.1	138.2 ± 64.2	39.0 ± 2.1
Male								
Control	3.6 ± 1.5	49.9 ± 13.7	58.8 ± 12.8	312.3 ± 66.9	0.56 ± 0.2	0.87 ± 0.17	101.8 ± 35.8	38.0 ± 4.3
250	3.7 ± 1.0	44.6 ± 14.8	47.6 ± 8.8	303.7 ± 78.9	0.44 ± 0.2	0.89 ± 0.33	96.3 ± 37.3	37.0 ± 2.7
500	4.5 ± 2.1	58.9 ± 17.0	63.4 ± 10.4	334.6 ± 93.4	0.46 ± 0.2	0.96 ± 0.54	95.3 ± 19.1	37.9 ± 1.8
1000	4.6 ± 1.6	52.8 ± 13.4	62.1 ± 14.4	307.8 ± 85.6	0.63 ± 0.2	0.95 ± 0.40	119.0 ± 77.2	37.6 ± 0.8

Data are presented as mean ± SD. Each group included 12 animals.

No significant differences were observed among groups, Dunnett's Test, $p > 0.05$.

Table 2. Haematological parameters in rats after 28 days of mangiferin oral administration.

Dose (mg/kg)	Platelets ($\times 10^9/L$)	Leucocytes ($\times 10^9/L$)	Lymphocytes (%)	Monocytes (%)	Eosinophils (%)	Hematocrit (%)	Hemoglobin (g/dl)	Erythrocytes ($\times 10^{12}/L$)
Female								
Control	313.3 ± 89.6	9.1 ± 2.5	79.6 ± 2.3	2.1 ± 1.0	1.5 ± 1.2	44.4 ± 1.5	14.7 ± 0.6	8.0 ± 0.5
250	350.8 ± 76.2	8.5 ± 2.2	82.1 ± 2.4	2.9 ± 1.0	1.1 ± 1.3	45.2 ± 1.7	14.4 ± 0.9	7.7 ± 0.5
500	361.7 ± 51.2	9.8 ± 1.5	81.3 ± 2.6	2.2 ± 1.8	1.0 ± 1.3	44.2 ± 1.8	14.4 ± 0.8	7.6 ± 0.4
1000	319.5 ± 85.7	8.7 ± 3.0	80.8 ± 1.4	1.5 ± 0.9	2.0 ± 1.9	46.6 ± 4.5	14.8 ± 1.0	7.9 ± 0.3
Male								
Control	342.9 ± 84.4	9.9 ± 2.30	79.9 ± 2.1	2.7 ± 1.2	1.2 ± 1.0	45.9 ± 4.5	15.2 ± 0.3	8.2 ± 0.2
250	335.8 ± 99.8	8.5 ± 1.99	80.6 ± 1.7	1.9 ± 1.0	1.1 ± 0.8	44.3 ± 2.6	15.9 ± 0.6	7.8 ± 0.9
500	365.8 ± 84.7	9.7 ± 2.97	79.0 ± 2.9	2.3 ± 0.6	1.2 ± 0.9	46.9 ± 1.8	15.2 ± 0.9	8.1 ± 0.7
1000	367.3 ± 79.5	9.8 ± 3.37	80.0 ± 1.6	2.8 ± 1.3	1.1 ± 0.6	46.2 ± 2.6	15.2 ± 0.9	8.2 ± 0.5

Data are presented as mean ± SD. Each group included 12 animals.

No significant differences were observed among groups, Dunnett's Test, $p > 0.05$.

Table 3. Relative organ weight in rats after 28 days of mangiferin oral administration.

Dose (mg/kg)	Heart (%)	Liver (%)	Lungs (%)	Kidneys (%)	Spleen (%)	Thymus (%)	Brain (%)
Female							
Control	0.39 ± 0.08	3.02 ± 0.52	0.60 ± 0.12	0.88 ± 0.20	0.24 ± 0.04	0.24 ± 0.08	0.52 ± 0.12
250	0.38 ± 0.04	3.07 ± 0.25	0.63 ± 0.08	0.80 ± 0.17	0.25 ± 0.04	0.25 ± 0.04	0.63 ± 0.08
500	0.36 ± 0.04	2.89 ± 0.24	0.59 ± 0.12	0.72 ± 0.08	0.24 ± 0.04	0.24 ± 0.08	0.55 ± 0.12
1000	0.42 ± 0.13	3.42 ± 0.42	0.68 ± 0.13	0.97 ± 0.30	0.25 ± 0.04	0.21 ± 0.04	0.55 ± 0.04
Male							
Control	0.37 ± 0.09	2.77 ± 0.58	0.43 ± 0.06	0.78 ± 0.14	0.18 ± 0.03	0.18 ± 0.06	0.43 ± 0.06
250	0.35 ± 0.09	2.71 ± 0.59	0.47 ± 0.09	0.74 ± 0.18	0.19 ± 0.03	0.15 ± 0.03	0.38 ± 0.18
500	0.38 ± 0.06	2.91 ± 0.44	0.50 ± 0.12	0.82 ± 0.12	0.20 ± 0.03	0.17 ± 0.03	0.44 ± 0.06
1000	0.38 ± 0.11	2.66 ± 0.54	0.49 ± 0.08	0.76 ± 0.16	0.22 ± 0.05	0.19 ± 0.05	0.38 ± 0.05

Data are presented as mean ± SD. All groups included 12 animals.

% represent the relative weight of organs respect to body weight (100%).

No significant differences were observed between groups, Dunnett's Test, $p > 0.05$.

Table 4. Non-neoplastic histopathological lesions found in the pancreas after 28 days oral administration of mangiferin to Sprague-Dawley rats.

Observations	Mangiferin (mg/kg)			
	Control	250	500	1000
Female				
Apoptosis of the acinar cells	0/12	2/12	1/12	11/12
Cell mitosis (Metaphase)	0/12	1/12	0/12	0/12
Acinar cell necrosis (without inflammation)	0/12	0/12	0/12	11/12
Cluster of basophilic acinar cells with loss of the Zymogen granules	0/12	0/12	0/12	10/12
Vacuolar degeneration	0/12	0/12	0/12	9/12
Male				
Apoptosis of the acinar cells	0/12	2/12	0/12	11/12
Acinar cell necrosis (without inflammation)	0/12	0/12	0/12	10/12
Cluster of basophilic acinar cells with loss of the Zymogen granules	0/12	0/12	0/12	11/12
Vacuolar degeneration	0/12	0/12	0/12	10/12

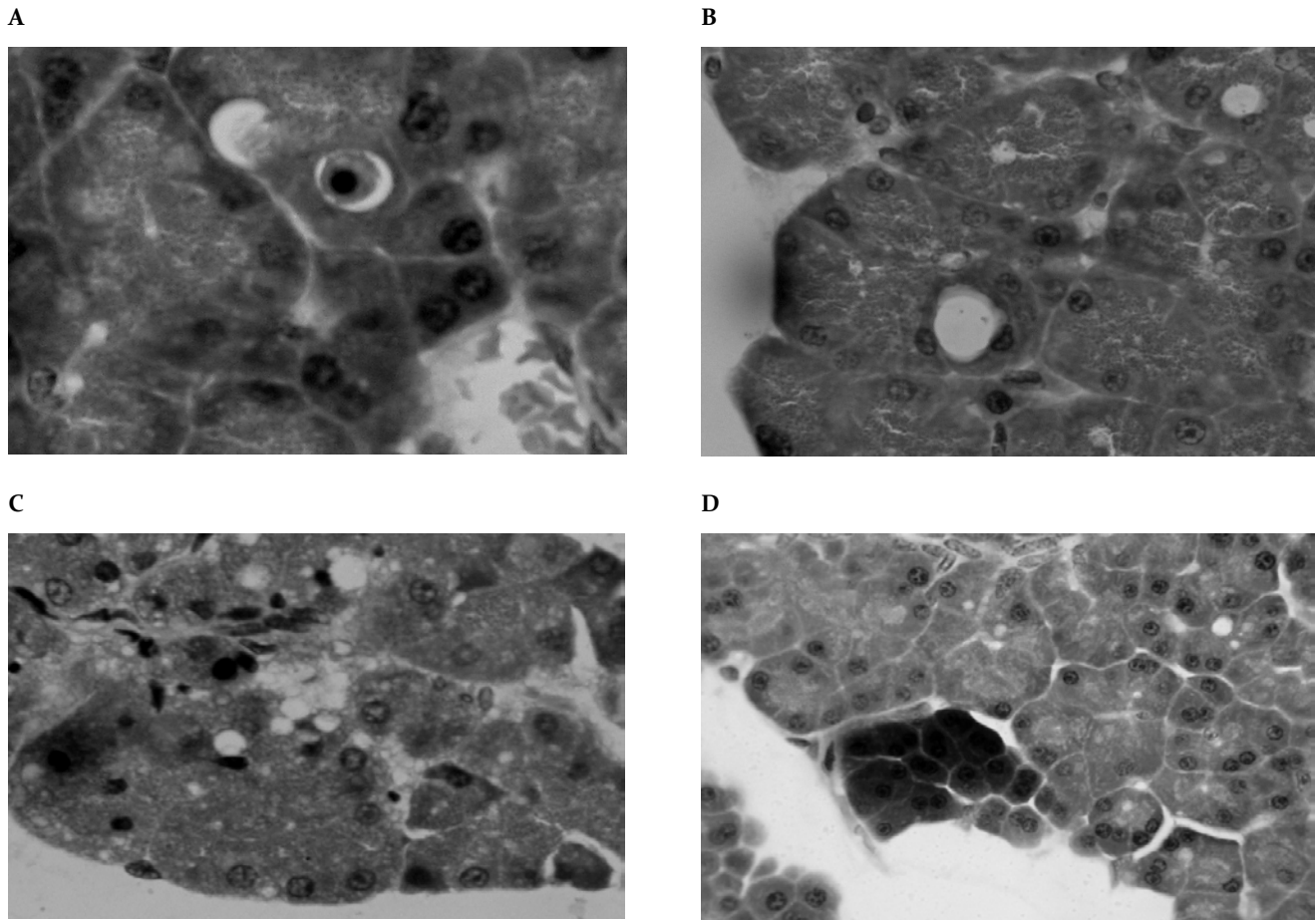


Figure 2. Photomicrograph showing pancreas from a representative animal of the doses of 1000 mg/kg with lesions in exocrine pancreatic acinar cells. (A) Exocrine pancreas with increased basophilia. (B) Cell apoptosis. (C) Acinar cell necrosis and loss of zymogen granules. (D) Vacuolar degeneration and loss of zymogen granules.

DISCUSSION

There are an increased number of recent reports regarding that polyphenols derived from plant sources may have the capacity to modulate the pathology of chronic diseases like cancer, diabetes, neurodegenerative disorders, cardiovascular disease and inflammatory and infectious processes (Aggarwal et al., 2006; Chen and Dou, 2008; Campos et al., 2009; Darvesh et al., 2010; Noratto et al., 2010). Therefore, many researchers are currently in the search of medicinal plants for extracting components thereof in order to support the cure

of these pathologies. However, all those possible candidates require medicinal health guarantees provided by the toxicological studies and an analysis of the action mechanisms. The toxicology studies with mangiferin described in this report provided the first tests to establish the safety of this product.

Exposure of Sprague-Dawley rats and Balb/C mice to oral and dermal single dose of mangiferin did not produce any treatment-related effect. The consequence of mangiferin exposure to 2000 mg/kg body weight in i.p. single dose by sex caused death in the animals. However, in another

study LD₅₀ value reported for mangiferin was 400 mg/kg after acute i.p. administration to DBAxC57BL mice (Jagetia and Baliga, 2005). We have previously reported that the mangiferin is neither cytotoxic nor mutagenic nor genotoxic in several *in vivo* and *in vitro* assays (Rodeiro et al., 2012). Similar results are reported for MSBE applied to Balb/C mice and Sprague-Dawley rats from both sexes in an acute toxicity assay (Garrido et al., 2009). MSBE is extracted from the mango tree; it is rich in polyphenols structures where mangiferin represents almost 20% of the polyphenol total (Nuñez et al., 2002). Thus, our present data agreed with the acute toxicological potential reported by these authors. Body weight and food consumption of the animals that survived regularly increased in accordance with the published values for the species (Alemán et al., 1998).

The exposure of male and female rats to 1000 mg/kg doses of mangiferin induced significant damage to the acinar cells of the exocrine pancreas at the repetitive doses assay. We explained this as diffuse non-inflammatory exocrine pancreas atrophy. The absence of inflammatory reaction in cases of induced exocrine pancreas atrophy was probably related to alterations in protein synthesis (Greaves and Faccini, 1984; Smith et al., 1982). Repeated doses of cyclosporine produce similar damage to the exocrine pancreas (Hirakawua et al., 1991). These authors suggest that prolonged treatments with cyclosporine may induce suppression of the exocrine pancreas function, probably because of the inhibition of DNA and protein synthesis. Therefore, the potential effects of mangiferin over protein synthesis should not be overlooked. Other authors have reported *in vitro* and *in vivo* anti-diabetic activity for mangiferin (Muruganandan et al., 2005; Li et al., 2010; Lin et al., 2010), which indicates that the pancreas is a pharmacological target for this molecule. However, the toxic signs were observed only at the highest dose levels of mangiferin (1000 mg/kg). Such toxic signs might be related to exacerbation of the pharmacological mechanism of mangiferin under these experimental conditions rather than an intrinsic cytotoxic effect. Accordingly, in order to corroborate this hypothesis, other studies should be performed.

CONCLUSIONS

In summary, we have demonstrated a low level of toxicity for orally administered mangiferin to rodents in acute and sub-chronic studies. Although some toxicity signs were observed in the repetitive dose assay, a wide safe margin is expected for orally administered mangiferin under our experimental conditions. A balance between therapeutic and toxicological effects of a new compound is an important parameter when verifying its applicability as a pharmacological drug. In our knowledge, the present study is the first battery of studies performed to investigate the mangiferin safety margin, a natural product under preclinical investigation as a candidate to a new phytomedicine.

CONFLICT OF INTEREST

The authors declare no conflict of interest.

ACKNOWLEDGEMENT

This work was partially supported by the projects PNAP-CIDEM 613007 (Cuba), VLIR-OUS 2011-062 (Belgium) and FONDECYT 1130601 (Chile).

REFERENCES

- Aggarwal BB, Shishodia S (2006) Molecular targets of dietary agents for prevention and therapy of cancer. *Biochem Pharmacol* 71: 1397-1421.
- Alemán C, Noa M, Rodeiro I, Hernandez C, Menendez R, Mas R (1998) Reference data base of the main physiological parameters in Sprague-Dawley rats from 6 to 32 months. *Lab Anim* 32: 457-466.
- Amazzal L, Lapotre A, Quignon F, Bagrel D (2007) Mangiferin protects against 1-methyl-4-phenylpyridinium toxicity mediated by oxidative stress in N2A cells. *Neurosci Lett* 418:159-164.
- Campos-Esparza MR, Sanchez-Gomez MV, Matute C (2009) Molecular mechanisms of neuroprotection by two natural antioxidant polyphenols. *Cell Calcium* 45: 358-368.
- Chen D, Dou PQ (2008) Tea polyphenols and their roles in cancer prevention and chemotherapy. *Intern J Mol Sci* 9: 1196-1206.
- Dar A, Faizi S, Naqvi S, Roome T, Zikr-Ur-Rehman S, Ali M, Firdous S, Moin ST (2005) Analgesic and antioxidant activity of mangiferin and its derivatives: the structure activity relationship. *Biol Pharm Bull* 28: 596-600.
- Darvesh AS, Carroll RT, Bishayee A, Geldenhuys WJ, Van der Schyf CJ (2010) Oxidative stress and Alzheimer's

- disease: dietary polyphenols as potential therapeutic agents. *Expert Rev Neurother* 10: 729-745.
- García D, Delgado R, Bougarne N, Haegeman G, Berghe WV (2011) Gallic acid indanone and mangiferin xanthone are strong determinants of immunosuppressive antitumour effects of *Mangifera indica* L. bark in MDA-MB231 breast cancer cells. *Cancer Lett* 305: 21-31.
- Garrido G, Delgado R, Lemus Y, Rodríguez J, García D, Núñez AJ (2004) Protection against septic shock and suppression of tumor necrosis factor alpha and nitric oxide production on macrophages and microglia by a standard aqueous extract of *Mangifera indica* L. (Vimang®). Role of mangiferin isolated from the extract. *Pharmacol Res* 50: 165-172.
- Garrido G, Martínez G, Pardo G, García D, Hernández P, Rodeiro I, Guevara M, Delgado R, Nuñez A (2007) Recent advances in the research & development of an aqueous stem bark extract obtained from *Mangifera indica* L. In: Capasso A, ed. *Recent Developments in Plants Research*. Kerala: Research Signpost, pp. 169-192.
- Garrido G, Rodeiro I, Hernández I, García G, Pérez G, Merino N, Nuñez A, Delgado R (2009) *In vivo* acute toxicological studies of an antioxidant extract from *Mangifera indica* L. (Vimang). *Drug Chem Toxicol* 32: 53-58.
- Garrido-Suarez B, Garrido G, Castro M, Merino N, Valdés O, Rodeiro I, Hernández I, Godoy J, Ferreira SH, Delgado R (2014) Anti-hypernociceptive effect of mangiferin in persistent and neuropathic pain models in rats. *Pharmacol Biochem Behav* 124:311-9.
- Govindaraj Y, Melanaphuru V, Agrahari V (2009) Genotoxicity studies of mangiferin isolated from *Salacia chinensis* Linn. *Acad J Plant Sci* 2: 199-204.
- Greaves P, Faccini JM (1984) *Rat histopathology. A glossary for use in toxicity and carcinogenicity studies*. New York, USA: Elsevier Science Publishers B.V.
- Hirakawua K, Ohkuma S, Kuriyama K (1991) Functional and morphological changes of the exocrine pancreas in cyclosporine treated rats. *Eur Sur Res* 23: 5-6.
- Jagetia GC, Baliga MS (2005) Radioprotection by mangiferin in DBAxC57BL mice: a preliminary study. *Phytomedicine* 12: 209-215.
- Lee B, Trung TH, Bae EA, Jung K, Kim DH (2009) Mangiferin inhibits passive cutaneous anaphylaxis reaction and pruritus in mice. *Planta Med* 75: 1415-1417.
- Leiro J, Alvarez E, Arranz J, Gonzalez I, Orallo F (2004) *In vitro* effects of mangiferin on superoxide concentrations and expression of the inducible nitric oxide synthase, tumor necrosis factor-alpha and transforming growth factor genes. *Biochem Pharm* 65: 1361-1371.
- Li X, Cui X, Sun X, Li X, Zhu Q, Li W (2010). Mangiferin prevents diabetic nephropathy progression in streptozotocin-induced diabetic rats. *Phytother Res* 24: 893-899.
- Lin H, Chen R, Liu X, Sheng F, Zhang H (2010) Study on interaction of mangiferin to insulin and glucagon in ternary system. *Spectrochim Acta A Mol Biomol Spectrosc* 75: 1584-1591.
- Muruganandan S, Srinivasan K, Gupta S, Gupta PK, Lal J (2005) Effect of mangiferin on hyperglycemia and atherogenicity in streptozotocin diabetic rats. *J Ethnopharmacol* 97: 497-501.
- Noratto GD, Bertoldi MC, Krenek K, Talcott ST, Stringheta PC, Mertens-Talcott SU (2010) Anticarcinogenic effects of polyphenolics from mango (*Mangifera indica*) varieties. *J Agric Food Chem* 58: 4104-4112.
- Núñez AJ, Castro H, Agüero-Agüero J, González J, Naddeo F, De Simone F, Rastrelli L (2002) Isolation and quantitative analysis of phenolic antioxidants, free sugars and polyphenols from Mango (*Mangifera indica* L.) stem bark aqueous decoction used in Cuba as a nutritional supplement. *J Agric Food Chem* 50: 762-766.
- Núñez AJ, Delgado R, Garrido G, García D, Guevara M, Pardo G (2009) The paradox of natural products as pharmaceuticals. Experimental evidences of a mango stem bark extract. *Pharmacol Res* 55: 351-358.
- OECD (2000) Guideline for the testing of chemicals, No. 423. Acute oral toxicity acute toxic class method. Paris, France: Organization for Economic Cooperation and Development.
- OECD (2004) OECD Guideline for testing of chemicals, No. 434. Acute dermal toxicity-fixed dose procedure. Paris, France: Organization for Economic Cooperation and Development.
- Pauletti PM, Castro-Gamboa I, Siqueira DH, Young MC, Tomazela DM, Eberlin MN (2003) New antioxidant C-glucooxylxanthones from the stems of *Arrabidaea samyoides*. *J Nat Prod* 66: 1384-1387.
- Prabhu S, Narayan S, Devi CS (2009) Mechanism of protective action of mangiferin on suppression of inflammatory response and lysosomal instability in rat model of myocardial infarction. *Phytother Res* 23: 756-760.
- Rajendran P, Ekambaram G, Sakthisekaran D (2008) Protective role of mangiferin against benzo(a)pyrene induced lung carcinogenesis in experimental animals. *Biol Pharm Bull* 31: 1053-1058.
- Rodeiro I, Delgado R, Garrido G (2014) Effects of a *Mangifera indica* L. stem bark extract and mangiferin on the radiation-induced DNA damage in human lymphocytes and lymphoblastic cells. *Cell Prolif* 47: 48-55.
- Rodeiro I, Donato MT, Martinez I, Hernandez I, Garrido G, Gonzalez-Lavaut JA, Menendez R, Laguna A, Castell JV, Gómez-Lechón MJ (2008) Potencial hepatoprotective effects of new Cuban natural products in rat hepatocytes culture. *Toxicol In Vitro* 22: 1242-1249.
- Rodeiro I, Hernandez S, Morffi J, Herrera JA, Gómez-Lechón MJ, Delgado R, Espinosa-Aguirre J (2012) Evaluation of genotoxicity and DNA protective effects of mangiferin, a glucooxylxanthone isolated from *Mangifera indica* L. stem bark extract. *Food Chem Toxicol* 50: 3360-3366.

- Rodríguez JC, Rodeiro I, Hernández I, Delgado R (2014) Eficacia del tratamiento combinado de mangiferina con cisplatino y 5-fluorouracilo en células CT26.WT. *Rev Cubana Farm* 48: 4.
- Sanchez GM, Re L, Giuliani A, Nuñez AJ, Davison GP, Leon OS (2000) Protective effects of *Mangifera indica* L. extract, mangiferin and selected antioxidants against TPA-induced biomolecules oxidation and peritoneal macrophage activation in mice. *Pharmacol Res* 42: 565-563.
- Satish BS, Rao MV, Sreedevi B, Nageshwar R (2009) Cytoprotective and antigenotoxic potential of mangiferin, a glucosylxanthone against cadmium chloride induced toxicity in HepG2 cells. *Food Chem Toxicol* 47: 592-600.
- Smith PA, Suéter JP, Case RM (1982) Progressive atrophy of pancreatic acinar tissue in rats fed a copper-deficient diet supplemented with D-penicillamine or triethylene tetramine: morphological and physiological studies. *Digestion* 23: 16-30.
- Tolosa L, Rodeiro I, Donato MT, Herrera J, Delgado R, Castell J, Gomez-Lechon MJ (2013) Multiparametric evaluation of the cytoprotective effect of the *Mangifera indica* L. stem bark extract and mangiferin in Hep-G2 cells. *J Pharm Pharmacol* 65: 1073-1082.
- Viswanadh EK, Rao BN, Rao BS (2010) Antigenotoxic effect of mangiferin and changes in antioxidant enzyme levels of Swiss albino mice treated with cadmium chloride. *Hum Exp Toxicol* 29: 409-418.
- Wu JF, Chen SB, Gao JC, Song HL, Wu LJ, Chen SL, Tu PF (2008) Xanthone glycosides from herbs of *Polygala hongkongensis* Hems and their antioxidant activities. *J Asian Nat Prod Res* 10: 673-678.
-